J. Cosmet. Sci., 64, 1–8 (January/February 2013)

Enzymatically generated hydrogen peroxide reduces the number of acne lesions in acne vulgaris

NEELAM MUIZZUDDIN, STEVEN SCHNITTGER,
WANDA MAHER, DANIEL H. MAES, and
THOMAS MAMMONE, *Estèe Lauder Companies, Melville, NY*.

Accepted for publication May 9, 2012.

Synopsis

A major component to the etiology of acne is the growth and invasion by *Propionibacterium acnes*. Hydrogen peroxide is an excellent antimicrobial agent but is unstable in most formulations. We have developed a hydrogen peroxide generation system using the enzyme glucose oxidase and glucose. This system is stable in a simple formulation and nonirritating. In a short-term clinical study (4 days), this formulation was effective in reducing the individual lesion size and total number of inflammatory acne lesions. There was a 68% reduction in acne-induced inflammation and 61% reduction in acne size within 4 days of treatment. A long-term clinical study (6 weeks in use) displayed 56% reduction in total number of inflamed lesions and a 45% reduction in noninflamed lesions after 6 weeks. This suggests that topical enzymatically generated hydrogen peroxide may help alleviate acne.

INTRODUCTION

The pathogenesis of acne is complex, with strong evidence supporting the involvement of sebaceous hyperplasia, follicular hyperkeratinization, bacterial hypercolonization, as well as an immune reaction followed by inflammation (1). The pathological process of acne starts with the production of excessive sebum. Sebum lipids are a complex mixture of squalene, cholesterol, wax esters, and triglycerides. The triglycerides can be metabolized by bacterial enzymes to glycerol and free fatty acids.

Excessive sebum secretion and loosely bound corneocytes clog pores and create a moist, anaerobic environment where anaerobic microorganisms multiply and eventually provoke inflammatory reactions. Excessive sebum production has been attributed to elevated androgen levels. Androgens have been shown to increase both the size and the output of sebum of the sebaceous gland (2). Acne begins to develop with the increase in androgens during the prepubertal period. Conversely, antiandrogens have been shown to reduce sebum lipids and improve acne.

Acne is also characterized by improper epidermal differentiation of the lower portion of the infundibulum of the sebaceous follicle, where keratinocytes lining the infundibulum are hyperproliferative compared with normal skin. This improper epidermal differentiation leads to a clogged pore, creating a microenvironment favorable for *Propionibacterium* *acnes* growth. The excessive lipids and improper differentiation of the keratinocytes in the follicle encourages bacterial growth and causes a weakening of the epidermal barrier in this follicle. This allows the bacteria and/or their metabolites to migrate into the skin and contribute to the inflammation observed in the final stages of the acne process (2–4).

The final phase of comedone formation is the inflamed lesion. The bacterial infiltrate into the skin triggers inflammatory mediator production and cellular infiltrate. A variety of inflammatory mediators have been described in the acne lesion. These include interleukin-1α (IL-1α), IL-1β, and substance P (5). In addition, there is a reported increase in lymphocytic infiltrate and neutrophil infiltrate in the follicular region (6), further contributing to the inflammation associated with the acne lesion. This leads to further increased production of the proinflammatory cytokines, IL-1α and tumor necrosis factor-alpha by T cells and keratinocytes, leading to proliferation of both cell types (4).

The primary pathogenic agent implicated in the development of inflammatory and non-inflammatory acne is *P. acnes* (7,8). *P. acnes* is included in a family of anaerobic, non-spore-forming gram-positive rods. The use of antibiotics to treat acne began in the 1960s; however, in the last two decades several antibiotic-resistant strains have emerged (7–11). In addition to antibiotics, topical benzoyl peroxide (BP) (12,13) and salicylic acid have consistently been found to be effective in reducing acne lesions (14,15). Growing awareness of antibiotic-resistant *Propionibacterium* species has contributed toward increased use of topical and systemic differentiation agents like retinoid (16,17), which help reduce the hyperproliferation of keratinocytes and can inhibit the migration of leukocytes (1,6,9).

Glucose oxidase catalyzes the oxidation of β-D-glucose to gluconic acid by utilizing molecular oxygen as an electron acceptor with simultaneous production of hydrogen peroxide (18). Such production of hydrogen peroxide from sources of glucose like honey has been shown to possess potent antibacterial properties (19) and has been used in wound healing (20,21). We have developed a hydrogen peroxide generating system using the enzyme glucose oxidase and glucose in an emulsion system that is stable and nonirritating. This study was designed to evaluate the effect of this formulation system on reducing acne.

METHODS AND MATERIALS

IN VITRO CHALLENGE TEST

An *in vitro* microbial challenge test was used to determine if the test material was effective in eliminating microorganisms. Glucose oxidase (0.04%) and glucose substrate (0.36%), test material, were dissolved in tryptic soy broth (BD Difco, Sparks, MD) and challenged with five pools of viable microorganisms known to contaminate cosmetics. Elimination of these microorganisms was followed over a 7-day period (22,23).

Pool 1 Enterics contained *Klebsiella pneumoniae* (ATCC 1388), *Escherichia coli* (ATCC 8739), and *Enterobacter gergoviae* (ATCC 33028); Pool 2 Pseudomonas consisted of *Burkholderia cepacia* (ATCC 25416), *Pseudomonas stutzeri* (ATCC 17588), *Pseudomonas putida* (ATCC 49128), and *Pseudomonas aeruginosa* (ATCC 9027); Pool 3 Staphylococci contained *Staphylococcus aureus* (ATCC 6538) and *S. epidermidis* (ATCC 49134); Pool 4 consisted of yeast, *Candida albicans* (ATCC 10231); and Pool 5 consisted of mold *Aspergillus niger* (ATCC 16404).

The test material was prepared in sterile tryptic soy broth (BD Difco) and 20 g of each was transferred aseptically into five sterile containers. Each 20-g sample was inoculated with 0.1 ml of appropriate inoculums such that each bacteria and yeast pool contained 10^6 colonies, whereas the mold pool contained 10^5 colonies. The container was tightly closed and the inoculated sample was mixed thoroughly and then incubated at ambient temperature (20–25°C).

The samples were observed for viable microbes after 24 h, 48 h, and 7 days. At each time point, 1.0 ml of each well-mixed sample was transferred by a sterile pipette to test tubes containing 9-ml diluent (Trypticase Azolectin Tween Broth Base; BD Difco) creating a 1:10 dilution; of which 1.1 ml was dispensed into one sterile petri dish and 1.0 ml into another. Melted agar medium (15–20 ml) kept at 45–50°C was added to each petri dish and rotated to disperse the product and agar thoroughly. Tryptic soy agar (BD Difco) was used for inoculum Pools 1, 2, and 3 and potato dextrose agar (BD Difco) for inoculum Pools 4 and 5. Once the agar was solidified, the petri dishes were inverted and incubated at 32–35°C for 48 h (23).

After 48 h incubation, the petri dishes were examined for recovery of any inoculated organism. The number of colonies was counted on the petri dish representing the 1:10 dilution, and multiplied by 10, and then converted to its appropriate log value. The number of colonies counted on the petri dish representing the 1:100 dilution was multiplied by 100, and then converted to its appropriate log value. When there were no colonies present on the 1:10 or 1:100 dilution petri dishes, the count was represented by the log value of 0.0 (23).

CLINICAL

Part I: short-term effect. Material A: 10% BP formulation in an oil-in-water emulsion. Material B: glucose oxidase enzyme 0.08%, glucose substrate 0.64% in an oil-in-water emulsion. Material C: glucose oxidase enzyme 0.5%, glucose substrate 4.0% in an oil-in-water emulsion.

Since the effect of hydrogen peroxide is pH dependent, the formulations were buffered at 7.0. There were no added ions such as copper and iron in these formulations.

The effect of the above materials was evaluated in a 1-week assay described previously (21). Ten women volunteers between the ages of 18 and 50 were recruited from a local population. All subjects were healthy with no evidence of acute or chronic disease other than acne. Written informed consent was obtained from each volunteer before entrance into the study. The panelists were not on any antibiotic, antihistamines, retinoid, anti-inflammatories or steroid therapy, and BP and/or salicylic acid treatment for at least 2 weeks before commencement of this study. The subjects were not under the care of a dermatologist and were not on any acne treatment for at least 1 month before the study started. Pregnant or lactating women were excluded. The panelists exhibited acne with at least two closed comedones on the upper back, minimum distances between closed comedones were approximately 4–6 cm.

Two inflamed acne lesions were selected for each treatment and one for the untreated. Each lesion was marked, photographed, and graded. A skin surface microscope (Scopeman;

Moritex, San Jose, CA) was used to visualize, size, and grade the lesion by two medical doctors at the testing lab. The lesions were treated and photographed every day for 5 days.

Part II: long-term effect. Thirty-eight women between the ages of 18 and 50 were recruited for the study, following the same inclusion and exclusion criteria as described in Part I. The panel was divided into three groups as follows: (i) Group A ($n = 15$), 2.5% BP in an oil-in-water emulsion; (ii) Group B ($n = 14$), 0.36% glucose oxidase substrate and 0.04% glucose oxidase enzyme in an oil-in-water emulsion; and (iii) Group C ($n = 9$), untreated control.

The formulations were buffered at pH 7.0. There were no added ions such as copper and iron in these formulations.

The panelists exhibited Grade 2 acne (10–30 papules and comedones over about one-fourth of the face) to Grade 4 (about half the face had papules, comedones, and a few pustules; some lesions were red and inflamed), or subtypes 1 (erythematotelangiectatic) and 2 (papulopustular) rosacea (National Rosacea Society).

This was a 6-week in-use study where the subjects applied the test material on their full face, twice a day. They were examined at baseline (before treatment) and after 2 and 6 weeks of treatment with their assigned test materials. At each time point, lesions of the full face were counted by trained personnel at the contract testing laboratories. Both inflammatory and noninflammatory lesions were counted. Since treatment was on full face every day, only the lower concentrations tested in the short-term assay were tested in the long-term assay, to avoid any irritation.

RESULTS

IN VITRO CHALLENGE TEST

Microbiological challenge testing is a useful tool for determining the ability of a material to support the growth of spoilage organisms or pathogens. As observed in Table I, the glucose oxidase and glucose substrate mixture were very effective against Pools 1–3, but not against yeast and molds.

CLINICAL

Part I: short-term effect. Short-term lesion reduction study exhibited a marked reduction in lesion size on the site treated with the formulations containing glucose oxidase and glucose during course of the study (Figure 1A). As observed in the graph, there was a distinct reduction in acne lesion size on the site treated with 0.5% glucose oxidase enzyme and 4% glucose ($p = 0.041$). The degree of inflammation on acne sites is shown in Figure 1B. As observed in the graph, there was a marked reduction in acne lesion size on the site treated with the formulation containing 0.5% glucose oxidase enzyme and 4% glucose ($p = 0.0467$). The lower concentration of these actives was almost as effective as 10% BP, which did not exhibit statistically significant improvement as compared to the untreated site.

Area under the curves from Figures 1A and B are described in Figure 2. Area under the curve is a complete and comprehensive representation of the lesion over the course of

Table I
Survival Ability of Selected Microorganisms That Were Introduced into a Mix of 0.04% Glucose Oxidase and 0.36% Glucose Substrate

Pools	Inoculum	24 h	48 h	Week 1
1	6.6	0	0	0
2	6.5	0	0	0
3	6.3	0	0	0
4	6.4	6.0	6.0	6.0
5	5.0	5.0	5.0	5.0

All numbers are expressed as log counts.

5 days. Percent difference compared with the untreated site shows that the glucose oxidase formulation exhibited an improvement in acne that was slightly better than the 10% BP formulation; however, the difference was not statistically significant.

Part II: long-term effect. The 6-week, in-use study results are described in Figures 3A and B. Count of the inflammatory acne lesions (Figure 3A) shows that they resolve over time in untreated control sites, because of the normal immune defense system of the body. BP (2.5%) was significantly effective ($p < 0.001$) in reducing inflammatory acne lesions after 2-, 4-, and 6-week use. Glucose oxidase formulation was also significantly effective ($p < 0.001$), although not as effective as 2.5% BP.

Noninflammatory acne lesions (Figure 3B) were also significantly reduced by 2.5% BP after 2-, 4-, and 6-week use ($p < 0.001$). Glucose oxidase formulation was also significantly effective ($p \leq 0.05$).

DISCUSSION

A major component to the etiology of acne vulgaris is the proliferation of *P. acnes* in the follicular duct (21) as supported by the benefits of both topical and oral antibiotics (13) to alleviate acne. Topical erythromycin, clindamycin, and tetracycline (24) have all shown

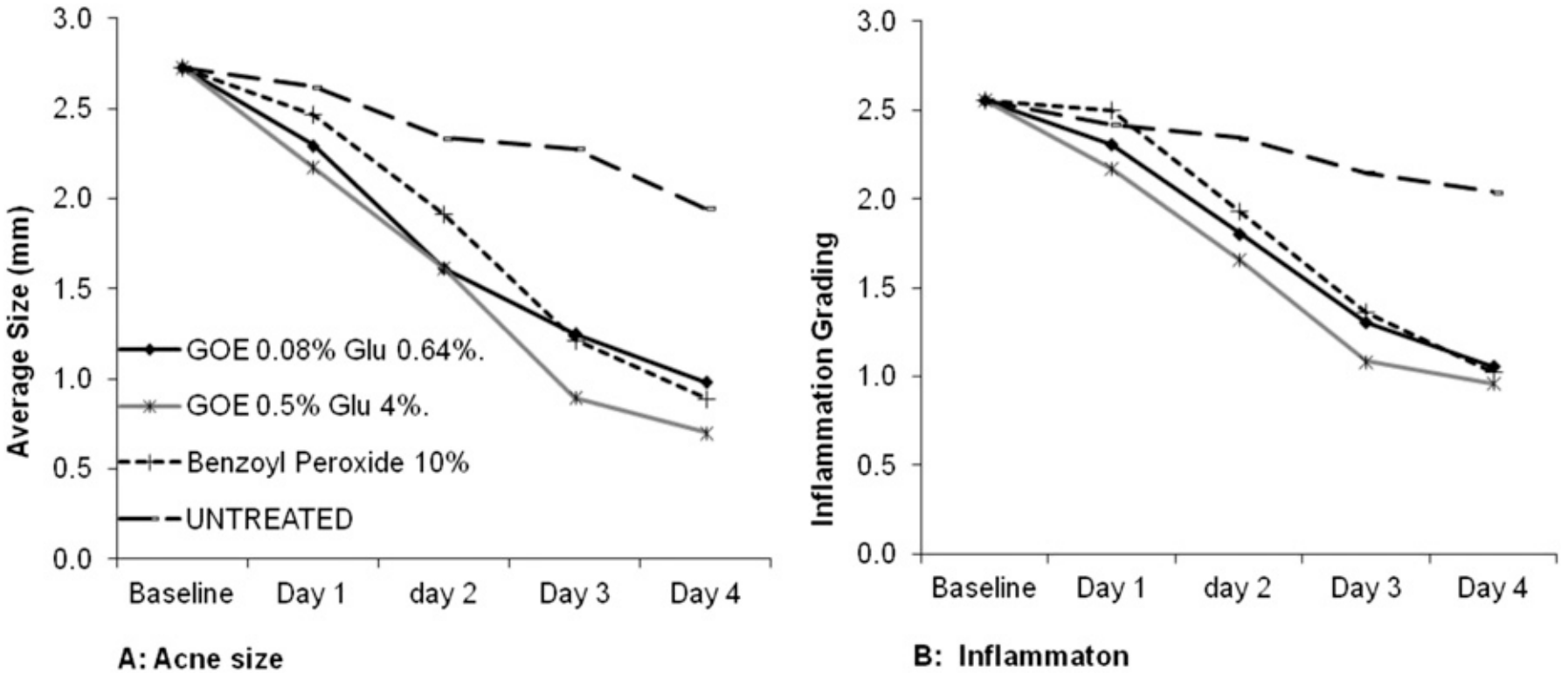

Figure 1. (A) Effect of glucose oxidase and glucose on reduction of size of acne lesion. (B) Reduction of inflammation of acne lesion. Size and inflammation of the individual acne lesions was assessed every day for 5 days with treatment.

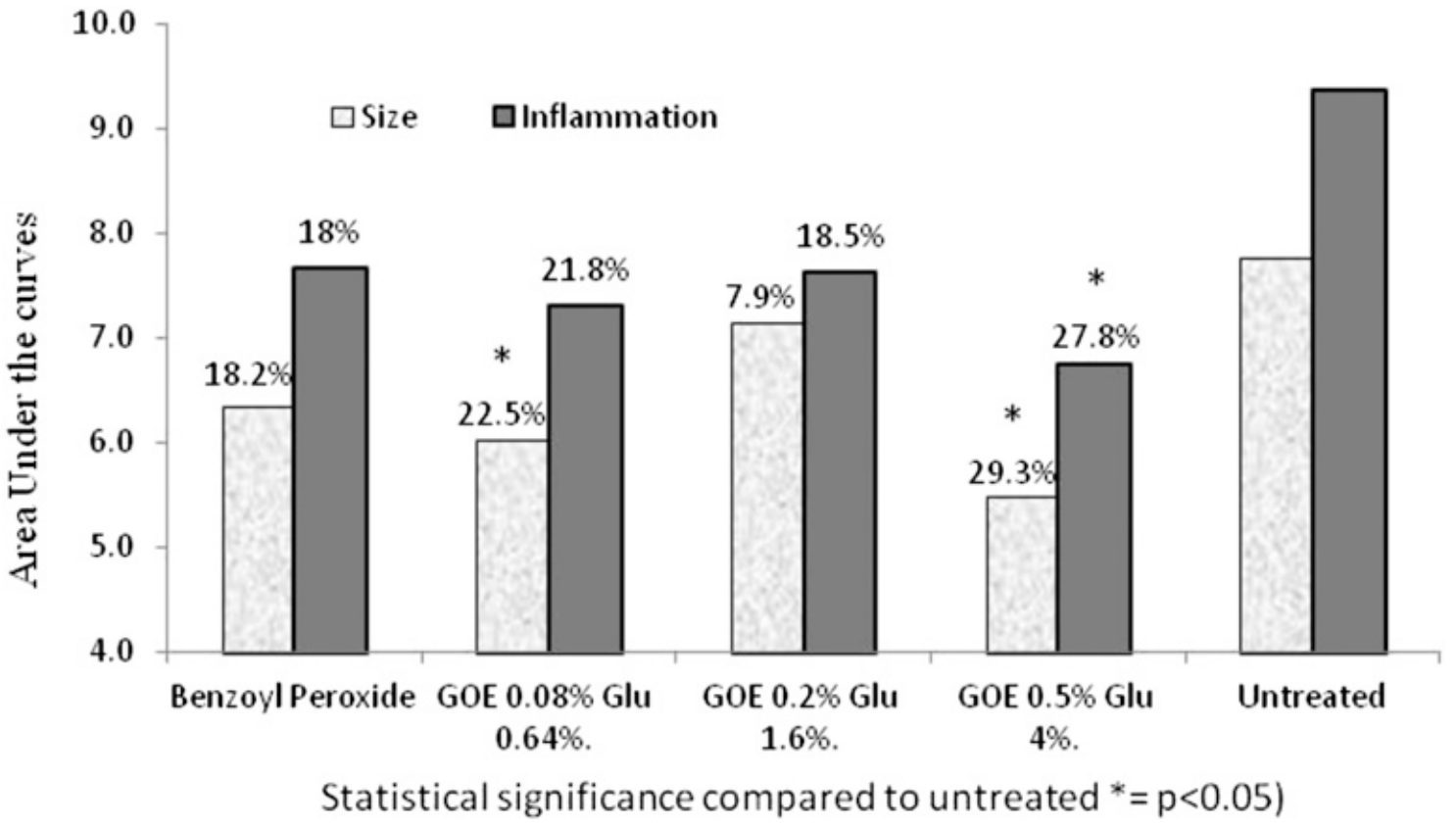

Figure 2. Area under the curves from Figures 1(A) and (B) showing a précis of the activity of each treatment on reduction of size and inflammation of acne lesions.

efficacy, whereas tetracyclines including doxycycline and minocycline are effective when taken orally (25–27). However, overuse of these antibiotics can lead to bacterial resistance (10) and have limited usefulness when used alone. One of the strongest antiseptics in common use is BP, which alone or in combination with other antibiotics can significantly reduce acne lesions and infection (28,13), however, with side effects like skin drying (28).

Hydrogen peroxide is a common antiseptic that is used diluted on skin to kill bacteria in a wound. It is a powerful oxidizing agent; however, it can act as a reducing agent for strong oxidants. Formulation of stable treatment creams with this agent is a challenge because of its reactive nature. Nevertheless, it has been shown to be a successful agent for acne treatment when used in combination with adapalene with better tolerability profile in comparison with the combination of BP and adapalene (27). Another study has shown hydrogen peroxide to be as effective as BP in reducing both inflammatory and noninflammatory acne vulgaris lesions in patients with mild-to-moderate disease, with a better local tolerability

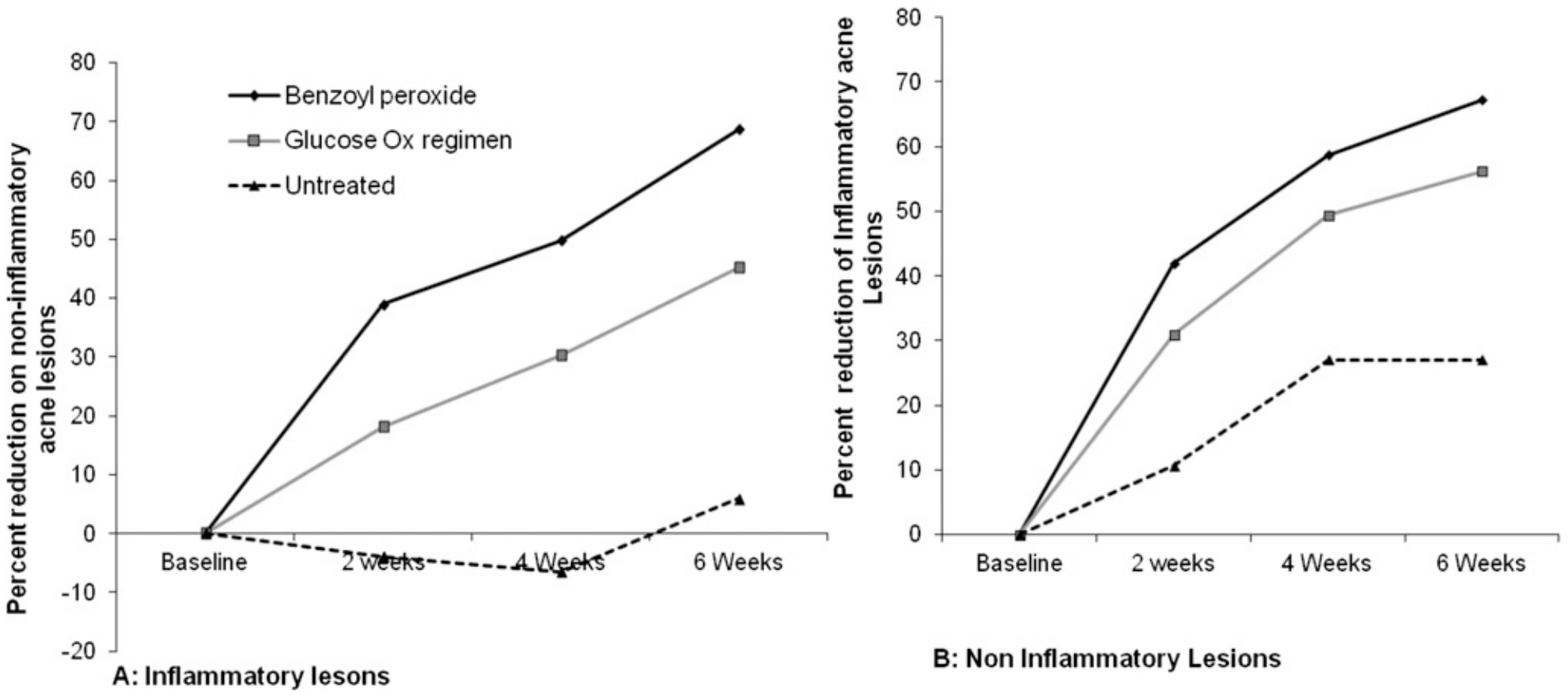

Figure 3. (A) Inflammatory lesion count of the full face from a 6-week in-use study. (B) Noninflammatory lesion count of the full face.

profile (29). We have developed an enzyme system that slowly generates hydrogen peroxide that can cleanse skin of bacteria. This enzymatically generated hydrogen peroxide appears to be as effective as BP but without the drying associated with it. On the basis of the confines and conditions of this study, there was a distinct reduction in acne lesion size and inflammation on the site treated with the formulations of glucose oxidase and glucose within days of treatment. There is not much known about the effect of long-term use of this system, nevertheless, it promises to be valuable in the reduction of the intensity of acne lesions without any harsh side effects and drug resistance as with antibiotics.

REFERENCES

1. N. Muizzuddin, "Acne: Causes, Treatment and Myths," in *Dermatology Research Focus on Acne Melanoma and Psoriasis*, D. E. Roth. Ed. (Nova Science Publishers, NY, 2009), pp. 97–106.
2. A. M. Al-Ameer and O. M. Al-Akloby, Demographic features and seasonal variations in patients with acne vulgaris in Saudi Arabia: a hospital-based study, *Int. J. Dermatol.*, **41**(12), 870–871 (2002).
3. I. B. Bassett, D. L. Pannowitz, and R. S. Barnetson, A comparative study of tea-tree oil versus benzoylperoxide in the treatment of acne, *Med. J. Aust.*, **153**(8), 455–458 (1990).
4. P. Lyte, R. Sur, A. Nigam, and M. D. Southall, Heat-killed *Propionibacterium acnes* is capable of inducing inflammatory responses in skin, *Exp Dermatol.*, **18**(12), 1070–1072 (2009).
5. B. Dreno, Topical antibacterial therapy for acne vulgaris, *Drugs*, **64**(21), 2389–2397 (2004).
6. H. Gollnick, Current concepts of the pathogenesis of acne: implications for drug treatment, *Drugs*, **63**(15), 1579–1596 (2003).
7. R. A. Bojar and K. T. Holland, Acne and *propionibacterium acnes*, *Clin. Dermatol.*, **22**(5), 375–379 (2004).
8. S. A. Buchner, Acne and its drug treatment, *Ther. Umsch.*, **47**(8), 670–674 (1990).
9. J. J. Leyden, Antibiotic resistance in the topical treatment of acne vulgaris, *Cutis*, **73**(Suppl. 6), 6–10 (2004).
10. G. A. Taylor and A. R. Shalita, Benzoyl peroxide-based combination therapies for acne vulgaris: a comparative review, *Am. J. Clin. Dermatol.*, **5**(4), 261–265 (2004).
11. L. Hegemann, S. M. Toso, K. Kitay, and G. F. Webster, Anti-inflammatory actions of benzoyl peroxide: effects on the generation of reactive oxygen species by leucocytes and the activity of protein kinase C and calmodulin, *Br. J. Dermatol.*, **130**(5), 569–575 (1994).
12. J. J. Leyden, Effect of topical benzoyl peroxide clindamycin versus topical clindamycin and vehicle in the reduction of *Propionibacterium acnes*, *Cutis*, **69**(6), 475–480 (2002).
13. C. M. Chronnell, L. R. Ghali, R. S. Ali, A. G. Quinn, D. B. Holland, J. J. Bull, W. J. Cunliffe, I. A. McKay, M. P. Philpott, and S. Muller-Rover, Human beta defensin-1 and -2 expression in human pilosebaceous units: upregulation in acne vulgaris lesions, *J. Invest. Dermatol.*, **117**(5), 1120–1125 (2001).
14. J. A. Cotterill, Benzoyl peroxide, *Acta Derm. Venereol. Suppl. (Stockh)*, (Suppl. 89), 57–63 (1980).
15. A. M. Kligman, The growing importance of topical retinoids in clinical dermatology: a retrospective and prospective analysis, *J. Am. Acad. Dermatol.*, **39**, S2–7 (1998).
16. S. Thevarajah, R. Balkrishnan, F. T. Camacho, S. R. Feldman, and A. B. Fleischer Jr., Trends in prescription of acne medication in the US: shift from antibiotic to non-antibiotic treatment, *J. Dermatolog. Treat.*, 16(4), 224–228 (2005).
17. S. B. Bankar, M. V. Bule, R. S. Singhal, and L. Ananthanarayan, Glucose oxidase—an overview, *Biotechnol. Adv.*, **27**(4), 489–501 (2009).
18. K. L. Allen, P. C. Molan, and G. M. Reid, A survey of the antibacterial activity of some New Zealand honeys, *J. Pharm. Pharmacol.*, **43**(12), 817–822 (1991).
19. P. E. Lusby, A. Coombes, and J. M. Wilkinson, Honey: a potent agent for wound healing? *J Wound Ostomy Continence Nurs.*, **29**(6), 295–300 (2002).
20. J. Betts, The clinical application of honey in wound care, *Nurs. Times*, **104**(14), 43–44 (2008).
21. N. Muizzuddin, D. Maes, and T. Mammone, A rapid method to clinically assess the effect of an anti-acne formulation, *J. Cosmet. Sci.*, **60**, 25–29 (2009).
22. D. K. Brannan, J. C. Dille, and D. J. Kaufman, Correlation of *in vitro* challenge testing with consumer use testing for cosmetic products, *Appl. Environ. Microbiol.*, **53**(8), 1827–1832 (1987).

23. Cosmetics Toiletries and Fragrance Association Inc, *Determination of Adequacy of Preservation of Cosmetic and Toiletry Formulations*, *CTFA Technical Guideline* (Cosmetics Toiletries and Fragrance Association Inc, Washington, DC, 1983).
24. D. R. Guay, Topical clindamycin in the management of acne vulgaris, *Expert Opin. Pharmacother.*, **8**(15), 2625–2664 (2007).
25. S. Purdy and D. de Berker, Acne vulgaris, *Clin. Evid.*, **5**, 1714 (2011).
26. K. M. Whitney and C. M. Ditre, Management strategies for acne vulgaris, *Clin. Cosmet. Investig. Dermatol.*, **4**, 41–53 (2011).
27. R. Capizzi, F. Landi, M. Milani, and P. Amerio, Skin tolerability and efficacy of combination therapy with hydrogen peroxide stabilized cream and adapalene gel in comparison with benzoyl peroxide cream and adapalene gel in common acne. A randomized, investigator-masked, controlled trial, *Br. J. Dermatol.*, **151**(2), 481–484 (2004).
28. W. J. Cuncliffe and K. T. Holland, The effect of benzoyl peroxide on acne, *Acta. Derm. Venereol.*, **61**(3), 267–269 (1981).
29. M. Milani, A. Bigardi, and M. Zavattarelli, Efficacy and safety of stabilised hydrogen peroxide cream (Crystacide) in mild-to-moderate acne vulgaris: a randomised, controlled trial versus benzoyl peroxide gel, *Curr. Med. Res. Opin.*, **19**(2), 135–138 (2003).