

## **Safety/Efficacy of New Topical Silicone Formulation with Selective Growth Factors for Treating Striae Distensae**

ROBIN KIKUCHI, ANDREA R. WALDMAN,  
ERIK M. WOLFSWINKEL, VADIM PLETZER,  
BRANDON D. KALASHO, and  
CHRISTOPHER I. ZOUMALAN, *Aesthetic and Reconstructive  
Oculoplastic Surgery, Beverly Hills, California 90212 (R.K., A.W.,  
B.K., C.I.Z.), Department of Plastic Surgery, Keck School of Medicine,  
University of Southern California, Los Angeles, California 90033 (E.M.W.),  
Division of Applied Statistics, Victoria University of Wellington,  
Wellington, New Zealand 6140 (V.P.)*

*Accepted for publication February 10, 2020.*

### **Synopsis**

Striae distensae (SD) are linear dermal scars that arise from progressive stretching or tearing of the dermal layer. This study tests the safety and efficacy of a topical formulation of silicone-based scar cream containing selective synthetic recombinant human growth factors, hyaluronic acid, and vitamin C to improve overall appearance and texture of SD. Twenty-two subjects with SD alba were recruited and randomized to apply the topical formula to half of their SD laterally twice a day for 1 month. Patient surveys were obtained at 1 month for overall appearance, texture, and tolerability. Three-dimensional imaging was obtained at baseline and at 1 month and submitted to independent evaluators for grading on overall appearance. Subjects reported improved texture and appearance in 86.4% of SD. Subjects reported 100% of untreated SD to have no change in overall appearance or texture. 90.9% of subjects reported no tolerability issues. 9.1% of the treated group reported mild issues such as slight itching or redness the first day of application, which subsided in 2 days for all patients. Independent evaluators indicated improvement in 72.7% of SD in comparison to improvement in 36.3% of untreated SD. This study demonstrates that the investigated topical formulation is safe and effective to use for SD.

### **INTRODUCTION**

Striae distensae (SD), or stretch marks, are linear dermal scars that arise from progressive stretching or tearing of the dermal layer. They are a cosmetic concern to a significant part of the general population, occurring in 50–90% of the general population following rapid weight changes during adolescence, pregnancy, or with corticosteroid use (1–3). The commonly affected areas include the abdomen, outer thighs, buttocks, axilla, and breasts. SD progress through three stages. They first appear as red inflammatory, pruritic,

---

Address all correspondence to [drchris@zoumalanmd.com](mailto:drchris@zoumalanmd.com).

and slightly raised striae, termed SD rubra. These then progress into a purple hue, termed SD purpuric. Finally, they progress to a chronic form where they appear hypopigmented and atrophic. This end state is often termed the final scar and referred to as SD alba (3–5).

Although they do not cause significant medical problems, aesthetically, SD can be a cause of great concern or psychological stress for many individuals. Thus, a variety of modalities have been attempted to treat SD, but there is no exemplar treatment that is currently available. Currently available treatment options range from topical creams to more invasive procedures, such as laser therapy, microneedling, and radiofrequency treatments. These invasive procedures have been shown to improve the appearance of SD to a variable degree, but they are often costly and require multiple treatment sessions at a physician's office, which can result in postprocedure downtime for the patient. Furthermore, complications associated with these treatments can include postinflammatory hyperpigmentation (PIH), which is common with lasers, as well as redness, pain, and edema, which are common issues with lasers, microneedling, and other devices such as radiofrequency (6–12).

From a practical standpoint, considering the cost of and access to treatments, topical creams are often the first-line treatment for SD in many patients (3). As a result, there is a multitude of topical products on the market, and many claims to improve the appearance of SD without any scientific evidence. Of particular note, there is some evidence in the literature to support the use of specific topical ingredients for reducing SD. For instance, ingredients such as selective growth factors, aloe vera, *Centella asiatica*, hyaluronic acid (HA), vitamin C, and silicone cream have all been shown to improve SD and postsurgical scars (12–22). In fact, a recent topical formulation using the ingredients mentioned earlier was used to evaluate postsurgical scars in a head-to-head double-blind prospective randomized multicenter trial. The findings demonstrated this formulation was 73% more effective than generic silicone cream in improving the appearance of scars (23).

Given the knowledge that SD are similar histologically to scars and often termed a dermal scar, we hypothesize that this same formulation that was shown to improve scars nearly 2 times better than silicone cream in postsurgical scars may provide improvement in the appearance of SD. In this study, we evaluate the safety and efficacy of a proprietary product that includes selective growth factors and other ingredients such as aloe vera, *Centella asiatica*, HA, and vitamin C within a silicone cream in treating SD.

## METHODS

This study investigates the safety and efficacy of a proprietary product in treating SD. The topical formulation consists of synthetic recombinant TGF- $\beta$ 3, HA, aloe vera extract, *Centella asiatica* extract, oil-soluble vitamin C, and several other synthetic recombinant human growth factors that are implicated in the wound-healing process. The silicone portion consists of dimethicone 10%. The topical product is manufactured by MD Medical Designs, Inc. (Beverly Hills, CA). The protocol for the study was conducted according to the Declaration of Helsinki and the Health Insurance Portability and Accountability Act.

Subjects older than 18 years with SD of the abdomen, thighs, or buttocks were included in this study. Subjects with bothersome SD who were existing patients in the medical office of author C. I. Z. were included. Patients who had received previous treatments for the same SD, including laser resurfacing, radiofrequency, microneedling, or other topical treatments were excluded. In addition, female patients who were pregnant or breast feeding

Table I  
Patient-Reported Outcome

Score	0	1	2	3
Overall Appearance	No change	Mild improvement	Moderate improvement	Significant improvement
Texture	No change	Mild improvement	Moderate improvement	Significant improvement
Tolerability	No issues	Mild issues	Moderate issues	Severe issues

were also excluded from the study because of possible compounding factors in SD. Patients with SD alba were included in the study, and those with SD rubra or purpuric were excluded.

In this split study, participants were assigned based on a computer-generated randomization protocol such that half, laterally, of the subject’s SD were treated with the proprietary product and half were left untreated. Participants were instructed to massage the product into the designated SD two times per day for 1 mo.

Subjects were assessed at baseline and again at 1 mo. At the month 1 follow-up visit, patient-reported outcome surveys were obtained for each side. Subjects were asked to grade the overall appearance and texture of their SD as no change, mild, moderate, or significant improvement through a survey. Subjects were also asked to grade their tolerability of the product as no, mild, moderate, or severe issues (Table I). Last, subjects were asked if they would continue with this treatment, yes or no. Three-dimensional imaging was performed before treatment was administered and at the 1-mo follow-up visit using a standardized Canfield Vectra 3D imaging system (Canfield Scientific Inc., Parsippany, NJ). Two independent evaluators, both licensed physicians in their residency training (dermatologist and plastic and reconstructive surgeon), blinded to the study treatment, assessed the images before and after treatment and graded the appearance of each side on overall appearance: –1 indicating worsened appearance, 0 indicating no change, 1 indicating mild improvement, 2 indicating moderate improvement, and 3 indicating significant improvement (Table II, Figure 1). In addition, the evaluator was also asked to indicate which side appeared better overall, left or right.

RESULTS

Twenty-two subjects (20 females and two males) met the criteria and were enrolled in this study. This included 11 abdomen, four thigh, and seven buttock SD. All subjects had SD alba. The mean age of subjects was 36.5 (SD ± 9.8) years.

Table II  
Independent Evaluator Scale

Score	–1	0	1	2	3
Overall appearance	Worsened	No change	Mild improvement	Moderate improvement	Significant improvement




Figure 1. Independent evaluator grading scale.

PATIENT-REPORTED OUTCOMES

*Overall appearance.* After 1 mo of using the topical product, 40.9% of SD had shown mild improvement, 31.8% had shown moderate improvement, 13.6% had shown significant improvement, and 13.6% had no change in overall appearance. After 1 mo of no treatment, 100.0% of SD were reported as having no change in overall appearance (Table III, Figure 2).

*Texture.* After 1 mo of using the topical product, 50.0% of SD had shown mild improvement, 18.2% had shown moderate improvement, 18.2% had shown significant

Table III  
Patient-Reported Outcome, Average Scores for Overall Appearance

Treatment	Score	Proportion (%), N = 22 patients	95% margin of error
Topical product	No change	3/22 (13.6%)	±14.3%
	Mild improvement	9/22 (40.9%)	±20.5%
	Moderate improvement	7/22 (31.8%)	±19.5%
	Significant improvement	3/22 (13.6%)	±14.3%
No treatment	No change	22/22 (100.0%)	±0.0%
	Mild improvement	0/22 (0.0%)	±0.0%
	Moderate improvement	0/22 (0.0%)	±0.0%
	Significant improvement	0/22 (0.0%)	±0.0%

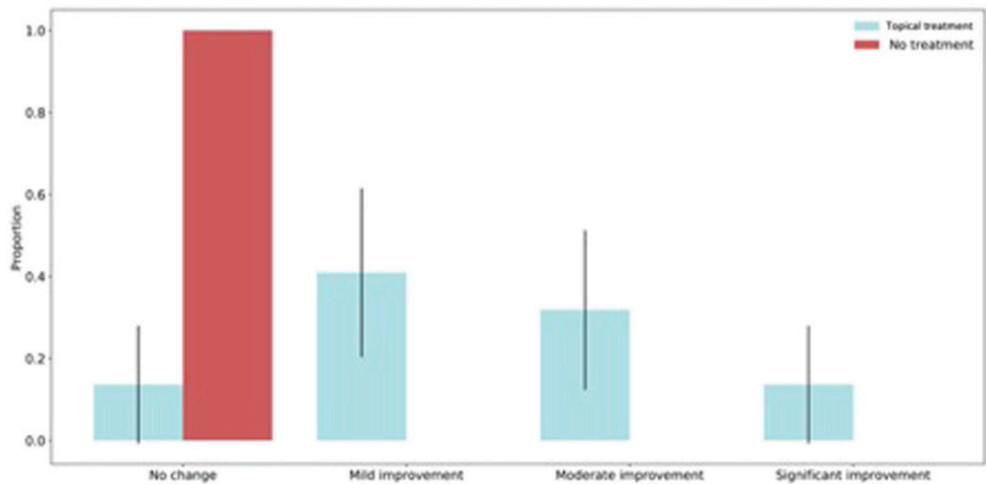


Figure 2. Patient reported overall appearance: Average distribution of scores.

improvement, and 13.6% had no change in texture. After 1 mo of no treatment, 100.0% of SD were reported as having no change in texture (Table IV).

*Tolerability.* The topical product was reported to be tolerated well and with no issues in 90.9% of cases (Table V). Overall, 9.1% of the treated group reported mild issues such as slight itching or redness the first day of application, which subsided by day 2 in all patients. In all, 86.4% of SD treated with the topical product were rated as having better overall appearance and texture by patients (Figure 3) and 0.0% of untreated SD were rated as having better overall appearance and texture. This was verified to be statistically significant by the Wilcoxon signed-rank test. Overall, 90.9% of SD treated with the topical product and untreated SD were rated the same for favorable tolerability to treatment and 9.1% of untreated SD had better ratings for tolerability to treatment. However, a Wilcoxon signed-rank test found there to be no statistically significant differences between SD treated with the topical product and untreated SD in response to tolerability to treatment. And, 20 of 22 patients (90.9%) indicated they would continue to use the topical product after the 1-mo duration of the study.

Table IV  
Patient-Reported Outcome, Average Scores for Texture

Treatment	Score	Proportion (%) N = 22 patients	95% margin of error
Topical product	No change	3/22 (13.6%)	±14.3%
	Mild improvement	11/22 (50.0%)	±20.9%
	Moderate improvement	4/22 (18.2%)	±16.1%
	Significant improvement	4/22 (18.2%)	±16.1%
No treatment	No change	22/22 (100.0%)	±0.0%
	Mild improvement	0/22 (0.0%)	±0.0%
	Moderate improvement	0/22 (0.0%)	±0.0%
	Significant improvement	0/22 (0.0%)	±0.0%

Table V  
Patient-Reported Outcome, Average Scores for Tolerability

Treatment	Score (count), N = 22 patients	Proportion (%), N = 22 patients	95% margin of error
Topical product	No issues	20/22 (90.9%)	±12.0%
	Mild issues	2/22 (9.1%)	±12.0%
	Moderate issues	0/22 (0.0%)	±0.0%
	Severe intolerance	0/22 (0.0%)	±0.0%
No treatment	No issues	22/22 (100.0%)	±0.0%
	Mild issues	0/22 (0.0%)	±0.0%
	Moderate issues	0/22 (0.0%)	±0.0%
	Severe intolerance	0/22 (0.0%)	±0.0%

INDEPENDENT EVALUATOR DATA

*Overall appearance.* After 1 mo of using the topical product, 29.5% of SD had shown mild improvement, 34.1% had shown moderate improvement, 9.1% had shown significant improvement, 27.3% had no change in overall appearance, and none of the SD worsened. After 1 mo of no treatment, 29.5% of SD had shown mild improvement, 6.8% had shown moderate improvement, 61.4% had shown no change, 2.3% had worsened in overall appearance, and none had shown significant improvement (Table VI, Figure 4).

On average, 86.4% of SD that were treated with the topical product were rated as having better overall appearance by independent evaluators. On average, 0.0% of untreated SD

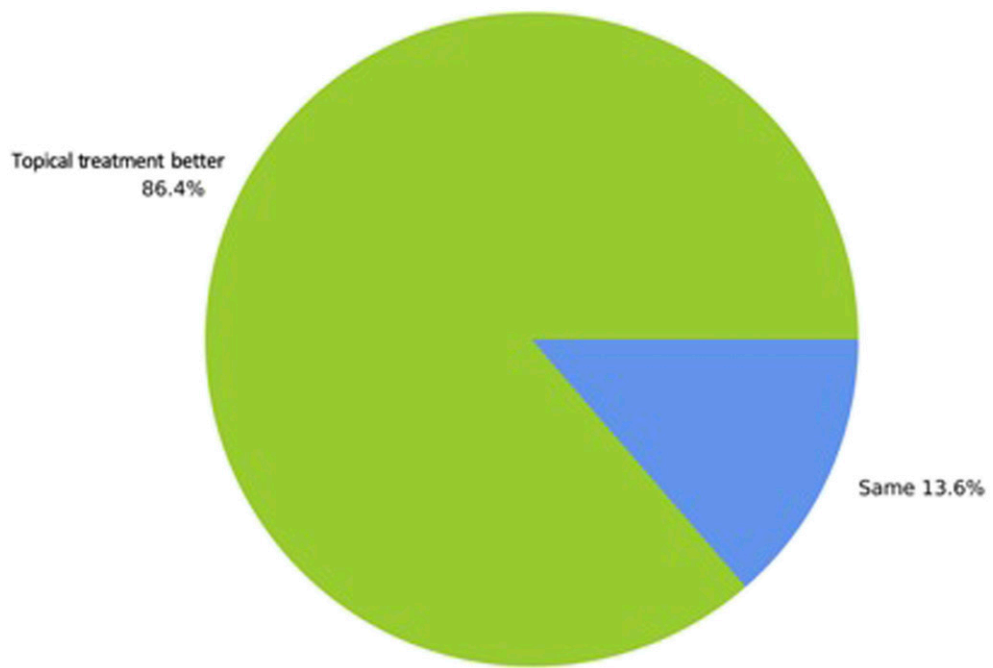


Figure 3. Patient reported average scores for overall appearance of topically treated SD.

Table VI  
Evaluator Average Scores for Overall Appearance

Treatment	Score	Proportion (%) <i>N</i> = 22 patients	95% margin of error
Topical product	Worsened	0/22 (0.0%)	±0.0%
	No change	6/22 (27.3%)	±13.2%
	Mild improvement	6.5/22 (29.5%)	±13.5%
	Moderate improvement	7.5/22 (34.1%)	±14.0%
	Significant improvement	2/22 (9.1%)	±8.5%
No treatment	Worsened	0.5/22 (2.3%)	±4.4%
	No change	13.5/22 (61.4%)	±14.4%
	Mild improvement	6.5/22 (29.5%)	±13.5%
	Moderate improvement	1.5/22 (6.8%)	±7.4%
	Significant improvement	0/22 (0.0%)	±0.0%

were rated as having better overall appearance. This was verified to be a statistically significant difference by the Wilcoxon signed-rank test (Table VII, Figure 5).

No adverse reactions were recorded over the duration of this study, and no patient discontinued the use of the topical product.

DISCUSSION

Based on evaluator grading, we saw improvement in 72.7% of treated SD over a period of 1 mo with our topical product. In addition, the majority of subjects (86.4%) indicated that they saw mild improvement or more to their treated SD (Figures 6–8). No subjects indicated a worsening in appearance of SD or intolerability of the product. Based on this study, the formulation was safe to use and well tolerated.

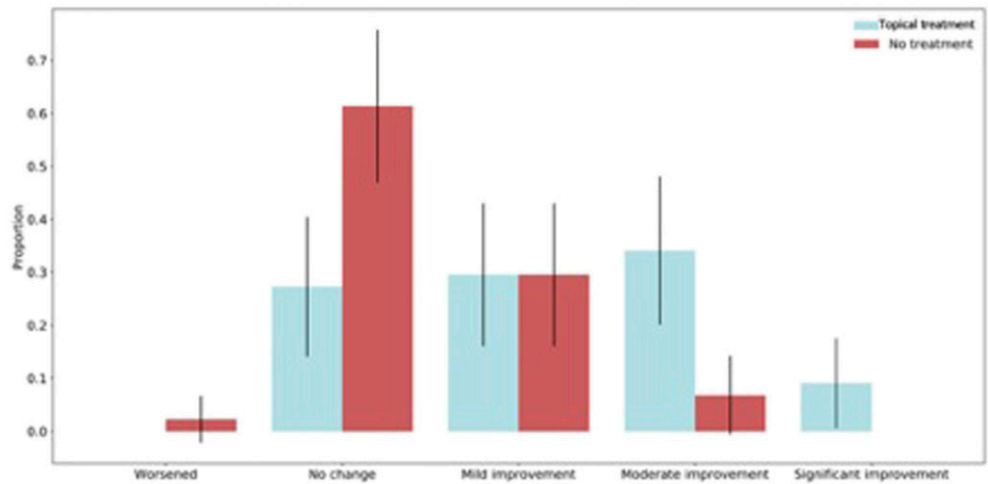


Figure 4. Evaluator overall appearance: Average distribution of scores.



Table VII  
Evaluator Average Scores for Overall Appearance

Side	Proportion (%)	95% margin of error
Topical product better	19/22 (86.4%)	±14.3%
Same	3/22 (13.6%)	±14.3%
No treatment better	0/22 (0.0%)	±0.0%

All of these ingredients used in the product we evaluated have been individually shown to improve SD in prior literature and, now, when collectively used in our topical formulation, SD improved significantly within 1 mo of use. We are unable to discern if there is a specific ingredient that may play a dominant role in the formulation, but it is most likely the improvement we saw is because of the synergistic effect of all the ingredients working along the surface of the skin.

There is evidence to support the use of silicone gel in treating SD. A recent study found that SD treated with silicone over a placebo cream had a statistically increased collagen and reduction in pigmentation (13). In addition, 2 recent studies demonstrated that silicone-based products improves SD in pregnant women (9,21). SD have histological similarities to scars, and silicone, which is used as the foundational matrix of our product, has a long track record as a scar-reducing treatment (24). In clinical trials, silicone has demonstrated effectiveness in preventing hypertrophic or keloid scarring in patients with newly healed wounds (25).

In addition, growth factors play a role in the progression of SD. A recent study indicated the positive effects of using growth factors to manage SD (12). Moreover, from a histologic standpoint, SD formation is similar to wound-healing processes found in scars

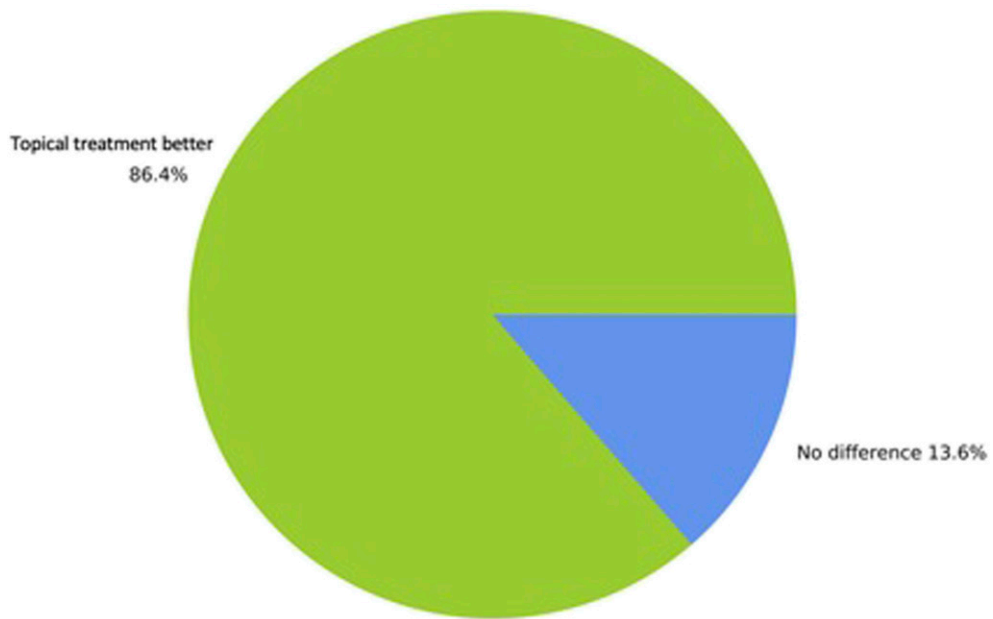
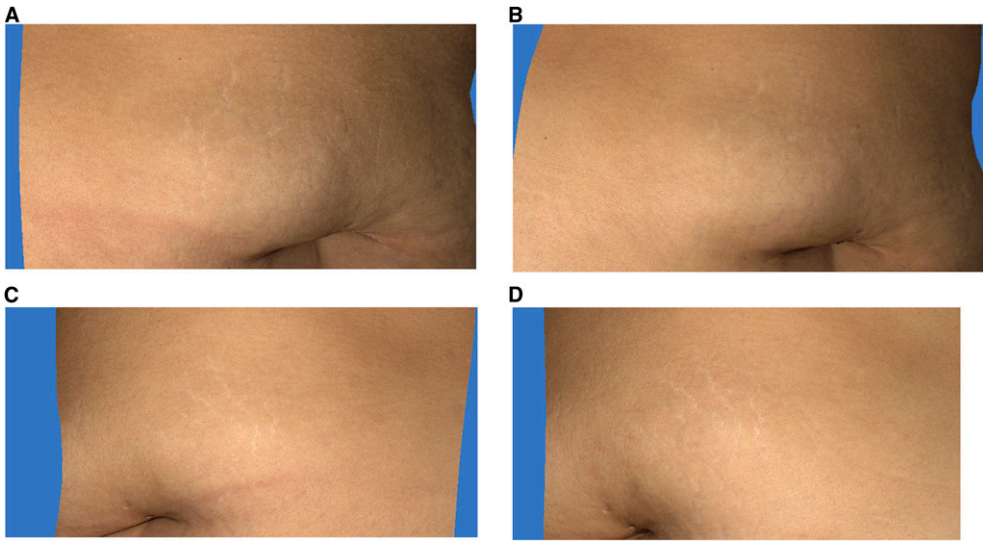


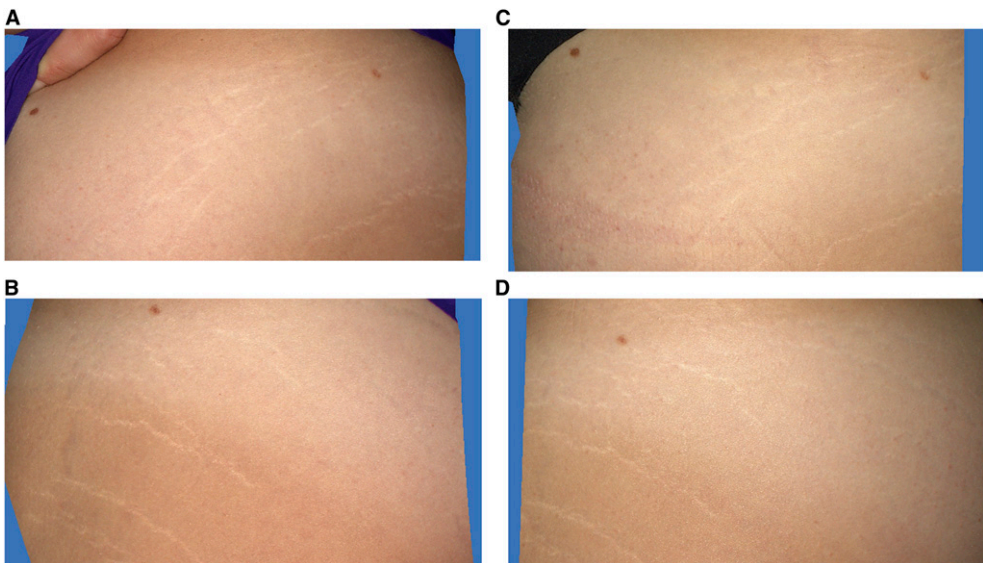
Figure 5. Evaluator average scores for overall appearance of topically treated SD.



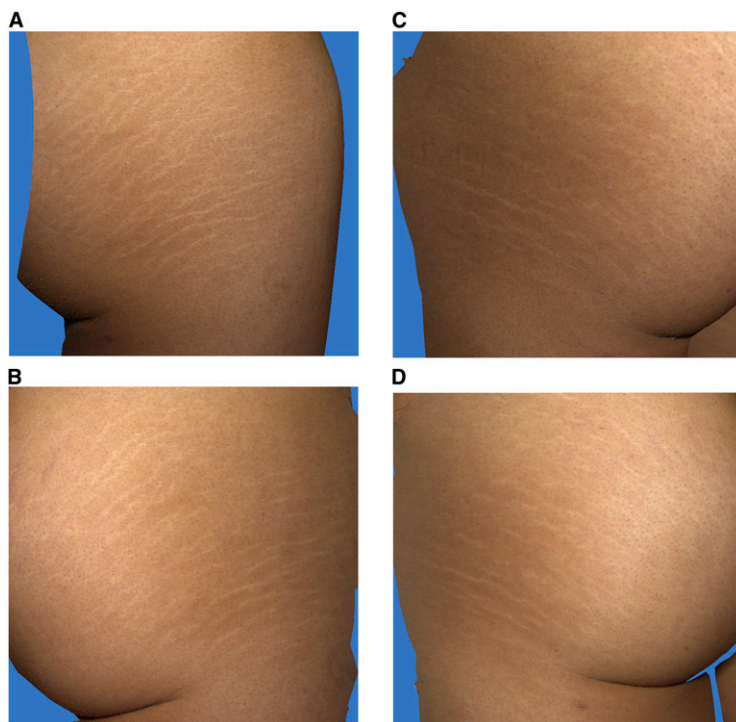


**Figure 6.** Three-dimensional photographic comparison of abdominal SD before and after 1-mo treatment with the topical product on one side (A) and no treatment on the other side (B). There is significant improvement in the overall appearance of SD on the side treated with the topical product (C). By contrast, the side left untreated (D) does not show improvement.

(4,26–28). The initial inflammatory, pruritic plaques evolve into stable, atrophic hypopigmented streaks that can be considered final scar tissue following the prior inflammatory changes. Anti-inflammatory and pro-inflammatory growth factors play a role in the transition of SD, and many believe that a disruption of the TGF- $\beta$  growth factor messenger



**Figure 7.** Three-dimensional photographic comparison of thigh SD before and after 1-mo treatment with the topical product on one side (A) and no treatment on the other side (B). There is moderate improvement in the overall appearance of SD on the side treated with the topical product (C). By contrast, the side left untreated (D) does not show improvement.



**Figure 8.** Three-dimensional photographic comparison of buttock SD before and after 1-mo treatment with the topical product on one side (A) and no treatment on the other side (B). There is mild improvement in the overall appearance of SD on the side treated with the topical product (C). By contrast, the side left untreated (D) does not show improvement.

pathway may be involved in striae formation (15,29). Decreased expression of collagen and fibronectin genes has also been associated with striae (30).

Vitamin C has also been shown to work well on stretch marks in prior literature (14,20). Vitamin C is an antioxidant used extensively in topical cosmeceuticals and moisturizers to prevent UV damage and improve skin quality (31). There is very strong evidence from an immunohistochemistry level that vitamin C is a potent stimulator of collagen and elastin production in the treatment of stretch marks (20). Vitamin C also stimulates collagen synthesis, which promotes wound healing. In scar treatments, topical application of vitamin C, in combination with silicone or HA, has also been shown to improve scar appearance (23,32,33).

HA has been shown to improve SD in prior literature (17). It is also implicated in fetal scarless healing. In fetal wounds, there is a prolonged elevation of high-molecular weight HA, whereas in adult wounds, there is transient elevation of low-molecular weight HA. Furthermore, HA receptor expression is elevated 2- to 4-fold in fetal fibroblasts, suggesting HA helps facilitate rapid fibroblast migration, which can help in improving SD as it does with scars (34).

Aloe vera has also been shown to improve SD (12,16). It has a long history of use in traditional medicine as a “healing plant” (35). Animal and clinical studies have shown that treatment with whole aloe vera gel or extracts leads to accelerated wound healing (35–37).

Aloe brings about its effect by promoting inflammatory cell infiltration, angiogenesis, extracellular matrix deposition, and epithelialization (35).

Last, *Centella asiatica* is very effective in wound healing and also has been shown to improve SD (18,19). It is used in traditional medicine as a treatment for wounds and scars (38). When applied to wounds, the extract increases cellular hyperplasia, collagen production, epithelialization, and angiogenesis, which accelerate collagen cross-linking, reepithelialization, wound maturation, and wound contraction, thus shortening the wound-healing process (39). On a molecular level, asiaticoside, an active ingredient of *Centella asiatica* extract, suppresses fibroblast proliferation, type I and type III collagen and mRNA expression, and TGF- $\beta$ RI and TGF- $\beta$ RII expression and increases Smad7 protein expression, which collectively suppress excessive scarring.

Although our formulation shows an improvement in SD, it does not completely eradicate them. Invasive procedures such as lasers, microneedling, and radiofrequency devices can potentially improve the appearance of SD more so than topical creams. However, there are downsides to such procedures such as the need for repeated procedures, high costs, discomfort or even pain during the procedure, and postprocedure complications such as swelling, redness, and PIH. Dover et al. (40) reported over 87% improvement in the appearance of SD in those who underwent six repeated sessions of radiofrequency treatment. However, postprocedure erythema and edema remained an issue (6,8). Other studies report up to 90% improvement in SD with either nonablative or ablative CO<sub>2</sub> fractional laser during three treatment sessions. However, nearly 82% reported PIH after procedure in the ablative CO<sub>2</sub> fractional group and experienced, on average, moderate pain during the procedure (11). Such high incidence of unwanted procedural sequela further supports the use of topical creams as a first-line agent to improve SD.

There are limitations to this study. The first limitation is that the participants were not blinded to treatment, which could lead to a bias toward the treated side. However, our two independent evaluators were both blinded, which increased the validity and reliability of the study, and saw an improvement in the side treated with the topical formulation similar to what the patients reported.

In addition, we did not evaluate whether patients would have a reduction in formation of new SD while using the cream. We only evaluated the improvement of their current stretch marks over time. We are aware of prior studies that showed a reduction of SD in pregnant women. Mallol et al. (18) demonstrated a reduction in SD from 56% in pregnant women who did not use the product to 34% in those who used the topical formulation that included *Centella asiatica*. A reduction in the intensity of SD that were seen in those who were using *Centella asiatica* was also noted in this study. Another study compared topical aloe vera to a placebo-based cream in pregnant women and found that the side on which aloe vera was used had only an 8% progression of SD in comparison to 65% progression of SD during pregnancy with base cream (16). This is an area of interest for future studies using our product.

Although that we did not evaluate our product in pregnant women, our topical product has been shown to be safe in our study. Furthermore, silicone cream and our other ingredients have all been shown to be safe in patients in prior studies with no adverse sequelae. This product should have no contraindications for pregnant women and young adults with SD.

We only had 1-mo follow-up period, but our study showed that there was a significant improvement in just 1 mo of using the topical product. Furthermore, nearly 90.9% of

our patients wished to continue using the product after the 1-mo period. Future research should follow the cohort for longer than 1 mo to uncover whether longer use of this product could result in potentially better outcomes.

Last, some may argue that the formulation's moisturizing vehicle by itself could induce enhanced moisturization of the skin and improve the appearance of SD. Future studies should use a split study of our formulation versus a placebo moisturizer.

## CONCLUSION

This study demonstrates that the investigated topical formulation is safe and effective to use for SD. It can help improve the appearance and texture of SD. It may also be considered for use in helping to prevent SD, as prior evidence supports the use of topical creams in preventing the formation of new SD, especially in pregnant women.

**Author Disclosure:** Christopher I. Zoumalan, MD, owns stock and is the scientific advisor for MD Medical Designs, Inc., Los Angeles, CA, manufacturer of the stretch mark cream used in this study.

## ACKNOWLEDGMENT

We thank Cristina Luna for her research-coordinating support.

## REFERENCES

- (1) A. L. S. Chang, Y. Z. Agredano, and A. B. Kimball, Risk factors associated with striae gravidarum, *J. Am. Acad. Dermatol.*, 51(6), 881–885 (2004).
- (2) K. H. Kelekci, S. Kelekci, E. Destegul, A. Aksoy, N. Sut, and B. Yilmaz, Prematurity: is it a risk factor for striae distensae? *Int. J. Dermatol.*, 50(10), 1240–1245 (2011).
- (3) A. Hague and A. Bayat, Therapeutic targets in the management of striae distensae: a systematic review, *J. Am. Acad. Dermatol.*, 77(3), 559–568 (2017).
- (4) B. J. Kim, D. H. Lee, M. N. Kim, K. Y. Song, W. I. Cho, C. K. Lee, and O. S. Kwon, Fractional photothermolysis for the treatment of striae distensae in Asian skin, *Am. J. Clin. Dermatol.*, 9(1), 33–37 (2008).
- (5) S. Kang, Topical tretinoin therapy for management of early striae, *J. Am. Acad. Dermatol.*, 39(2), S90–S92 (1998).
- (6) M. C. A. Issa, L. E. de Britto Pereira Kassuga, N. S. Chevrant, L. do Nascimento Barbosa, R. R. Luiz, L. Pantaleão, E. G. Vilar, and M. C. Rochaël, Transepidermal retinoic acid delivery using ablative fractional radiofrequency associated with acoustic pressure ultrasound for stretch marks treatment, *Laser Surg. Med.*, 45(2), 81–88 (2013).
- (7) S. Guida, M. G. Galimberti, M. Bencini, G. Pellacani, and P. L. Bencini, Treatment of striae distensae with non-ablative fractional laser: clinical and in vivo microscopic documentation of treatment efficacy, *Laser Med. Sci.*, 33(1), 75–78 (2018).
- (8) V. Mishra, L. Miller, S. M. Alsaad, and E. V. Ross, The use of a fractional ablative micro-plasma radiofrequency device in treatment of striae, *J. Drugs Dermatol. JDD*, 14(11), 1205–1208 (2015).
- (9) H. Bak, B. J. Kim, W. J. Lee, J. S. Bang, S. Y. Lee, J. H. Choi, and S. E. Chang, Treatment of striae distensae with fractional photothermolysis, *Dermatol. Surg.*, 35(8), 1215–1220 (2009).
- (10) F. Malekzad, S. Shakoei, A. Ayatollahi, and S. Hejazi, The safety and efficacy of the 1540nm non-ablative fractional XD probe of star lux 500 device in the treatment of striae alba: before-after study, *J. Lasers Med. Sci.*, 5(4), 194 (2014).



- (11) Y. J. Yang and G. Y. Lee, Treatment of striae distensae with nonablative fractional laser versus ablative CO<sub>2</sub> fractional laser: a randomized controlled trial, *Ann. Dermatol.*, 23(4), 481–489 (2011).
- (12) W. Disphanurat, A. Kaewkes, and W. Suthiwartnarueput, Comparison between topical recombinant human epidermal growth factor and Aloe vera gel in combination with ablative fractional carbon dioxide laser as treatment for striae alba: a randomized double-blind trial, *Laser Surg. Med.*, 52, 166–175 (2020).
- (13) S. Ud-Din, S. L. McAnelly, A. Bowring, S. Whiteside, J. Morris, I. Chaudhry, and A. Bayat, A double-blind controlled clinical trial assessing the effect of topical gels on striae distensae (stretch marks): a non-invasive imaging, morphological and immunohistochemical study, *Arch. Dermatol. Res.*, 305(7), 603–617 (2013).
- (14) P. Morganti, P. Palombo, G. Fabrizi, M. Palombo, and S. Persechino, Biweekly in-office injectable treatment of striae distensae vs a long-term daily use of topical vitamin C, *J. Appl. cosmetology*, 19(4), 107–112 (2001).
- (15) D. de Lacerda, Striae distensae: the fibrillin/transforming growth factor beta signaling puzzle, *Skinmed*, 10(6), 338 (2012).
- (16) M. Hajhashemi, M. Rafeian, H. A. Rouhi Boroujeni, S. Miraj, S. Memarian, A. Keivani, and F. Haghollahi, The effect of aloe vera gel and sweet almond oil on striae gravidarum in nulliparous women, *J. Maternal-Fetal Neonatal Med.*, 31(13), 1703–1708 (2018).
- (17) Z. D. Draelos, M. H. Gold, M. Kaur, B. Olayinka, S. L. Grundy, E. J. Pappert, and B. Hardas, Evaluation of an onion extract, *Centella asiatica*, and hyaluronic acid cream in the appearance of striae rubra, *Skinmed*, 8(2), 80–86 (2010).
- (18) J. Mallol, M. A. Belda, D. Costa, A. Noval, and M. Sola, Prophylaxis of striae gravidarum with a topical formulation. A double blind trial, *Int. J. Cosmet. Sci.*, 13(1), 51–57 (1991).
- (19) A. Sparavigna, M. Setaro, G. Manini, and C. Rigoni, Boswellic acid based cream is effective and well tolerated treatment for striae distensae, *J. Appl. Cosmetol.*, 23, 93–104 (2005).
- (20) A. Hinek, H. J. Kim, Y. Wang, Wang, A., and T. F. Mitt, Sodium L-ascorbate enhances elastic fibers deposition by fibroblasts from normal and pathologic human skin, *J. Dermatol. Sci.*, 75(3), 173–182 (2014).
- (21) C. D. G. Hughes and A. Hedges, The use of an innovative film-forming topical gel in preventing striae gravidarum and treating striae distensae, *Australas. J. Dermatol.*, 60(1), 78–80 (2019).
- (22) C. I. Zoumalan, Topical agents for scar management: are they effective? *J. Drugs Dermatol. JDD.*, 17(4), 421–425 (2018).
- (23) C. I. Zoumalan, S. C. Tadayon, J. Roostaeian, A. M. Rossi, and A. Gabriel, Safety and efficacy of a scar cream consisting of highly selective growth factors within a silicone cream matrix: a double-blinded, randomized, multicenter study, *Aesthet. Surg. J.*, 39, 319–330 (2019).
- (24) B. Bleasdale, S. Finnegan, K. Murray, S. Kelly, and S. L. Percival, The use of silicone adhesives for scar reduction, *Adv. Wound Care*, 4(7), 422–430 (2015).
- (25) K. C. Hsu, C. W. Luan, and Y. W. Tsai, Review of silicone gel sheeting and silicone gel for the prevention of hypertrophic scars and keloids, *Wounds*, 29(5), 154–158 (2017).
- (26) M. L. Elsaie, L. S. Baumann, and L. T. Elsaie, Striae distensae (stretch marks) and different modalities of therapy: an update, *Dermatol. Surg.*, 35(4), 563–573 (2009).
- (27) J. F. Hermanns and G. E. Piérard, High-resolution epiluminescence colorimetry of striae distensae, *J. Eur. Acad. Dermatol. Venereol.*, 20(3), 282–287 (2006).
- (28) G. S. S. Atwal, L. K. Manku, C. E. M. Griffiths, and D. W. Polson, Striae gravidarum in primiparae, *Br. J. Dermatol.*, 155(5), 965–969 (2006).
- (29) T. Leivo, P. Arjomaa, J. Oivula, M. Vesterinen, U. Kiistala, P. Autio, and A. Oikarinen, Differential modulation of transforming growth factor- $\beta$  by betamethasone-17-valerate and isotretinoin: corticosteroid decreases and isotretinoin increases the level of transforming growth factor- $\beta$  in suction blister fluid, *Skin Pharmacol. Physiol.*, 13(3–4), 150–156 (2000).
- (30) K. S. Lee, Y. J. Rho, S. I. Jang, M. H. Suh, and J. Y. Song, Decreased expression of collagen and fibronectin genes in striae distensae tissue, *Clin. Exp. Dermatol.*, 19(4), 285–288 (1994).
- (31) L. Chen, J. Y. Hu, and S. Q. Wang, The role of antioxidants in photoprotection: a critical review, *J. Am. Acad. Dermatol.*, 67(5), 1013–1024 (2012).
- (32) B. Amirlak, M. Mahedia, and N. Shah, A clinical evaluation of efficacy and safety of hyaluronan sponge with vitamin C versus placebo for scar reduction, *Plast. Reconstr. Surg. Glob. Open*, 4(7), e792 (2016).

- (33) I. S. Yun, H. S. Yoo, Y. O. Kim, and D. K. Rah, Improved scar appearance with combined use of silicone gel and vitamin C for Asian patients: a comparative case series, *Aesthet. Plast. Surg.*, 37(6), 1176–1181 (2013).
- (34) A. Leung, T. M. Crombleholme, and S. G. Keswani, Fetal wound healing: implications for minimal scar formation. *Curr. Opin. Pediatr.*, 24(3), 371 (2012).
- (35) A. Atiba, H. Ueno, and Y. Uzuka, The effect of aloe vera oral administration on cutaneous wound healing in type 2 diabetic rats, *J. Vet. Med. Sci.*, 73, 583–589 (2011).
- (36) S. W. Choi, B. W. Son, Y. S. Son, Y. I. Park, S. K. Lee, and M. H. Chung, The wound-healing effect of a glycoprotein fraction isolated from aloe vera, *Br. J. Dermatol.*, 145(4), 535–545 (2001).
- (37) P. Chithra, G. B. Sajithlal, and G. Chandrakasan, Influence of aloe vera on the healing of dermal wounds in diabetic rats, *J. ethnopharmacology*, 59(3), 195–201 (1998).
- (38) W. Bylka, P. Znajdek-Awiżeń, E. Studzińska-Sroka, A. Dańczak-Pazdrowska, and M. Brzezińska, *Centella asiatica* in dermatology: an overview, *Phytother Res.*, 28(8), 1117–1124 (2014).
- (39) S. S. Hong, J. H. Kim, H. Li, and C. K. Shim, Advanced formulation and pharmacological activity of hydrogel of the titrated extract of *C. asiatics*, *Arch. pharmacol Res.*, 28(4), 502–508 (2005).
- (40) J. S. Dover, K. Rothaus, and M. H. Gold, Evaluation of safety and patient subjective efficacy of using radiofrequency and pulsed magnetic fields for the treatment of striae (stretch marks), *J. Clin. Aesthet. Dermatol.*, 7(9), 30 (2014).